



## Features of Neuralization Diagnostics Transitor-Ischemic Attacks

Tursunova M. O<sup>1</sup>; Abdullaeva M. B<sup>2</sup>; Kalanov A. B<sup>3</sup>; Aktamova M. U<sup>4</sup>

<sup>1</sup> Independent Researcher, Tashkent State Dental Institute, Uzbekistan

<sup>2</sup> Associate Professor, Department of “Folk Medicine of Neurological Diseases”, Tashkent State Dental Institute, Uzbekistan

<sup>3</sup> Assistant, Department of “Folk Medicine of Neurological Diseases”, Tashkent State Dental Institute, Uzbekistan

<sup>4</sup> Student, Tashkent State Dental Institute, Uzbekistan

<http://dx.doi.org/10.18415/ijmmu.v8i7.2937>

---

### **Abstract**

Transient-ischemic attacks (TIA) as precursors of cerebral strokes occupy an important place among all forms of cerebrovascular insufficiency. With regard to the epidemiology of transient ischemic attacks (TIA), most countries do not have accurate data. So, in the US, they carry up to 5 million adult citizens per year, with many TIAs remaining undiagnosed. These episodes of sudden and short-term neurological deficit were considered benign and harmless for a long time. Most general practitioners and patients incorrectly or insufficiently understand the nature and significance of TIA, perhaps this can explain the small interest of doctors and the lack of statistical data on this nosological unit. Transient ischemic attacks (TIA) are defined clinically as rapidly occurring focal and less commonly diffuse (cerebral) dysfunctions of the brain that are caused by local ischemia and disappear within one day (Gafurov: 2006). Over the past two decades, many views on TIA have changed significantly; approaches to the diagnosis and treatment of patients have become much more intense and more aggressive. Current knowledge of TIA is of great importance both for the proper organization of patient care and for educational programs among the population, the importance of which cannot be overestimated.

**Keywords:** *Transient Ischemic Attack; Cardiomagnyl; Ischemic Stroke*

### **Introduction**

TIA should be considered an urgent situation for the following reasons:

- The first - the risk of ischemic stroke after TIA is quite high;
- Second - effective secondary prevention is available.

In this regard, an important early and reliable diagnosis of TIA, which, in turn, will allow the correct therapy of this pathology? In the diagnosis of TIA, the most widely used methods are Doppler ultrasound and computed tomography. As a rule, TIA is an acute episode in the general clinical picture of chronic progressive cerebral ischemia, in this regard; neuroimaging methods also reveal signs of dyscirculatory encephalopathy.

The most common cause of TIA in Western Europe and America in 80-90% of cases is atherosclerosis. Atherosclerotic multiple lesions are more common than isolated ones. So, according to A.A. Spiridonov (1996), the pathology of only one carotid artery occurs in 51.7% of cases. The defeat of one vertebral artery was noted in 38% of cases. The incidence of multiple BCA lesions ranges from 50 to 93.8%. The lesion of the BCA (brachiocephalic arteries) in 33% of cases is located intracranially, or in the zone of inaccessibility for direct surgical correction. The remaining 67% were extracranial, 52% of which were localized in the area of the CCA bifurcation, 20% in the area of the vertebral artery orifices, and 9% in the area of the main branches of the aortic arch.

### ***The Main Findings and Results***

In the structure of the causes of TIA, pathological deformities of the carotid and vertebral arteries occupy the second place. The reasons for the development of pathological deformities have not yet been finally established. Most authors believe that they are the result of congenital (impaired embryogenesis) or acquired factors (weakening of the elastic frame of the artery wall, atherosclerotic lesions of the arteries, age-related anatomical changes in the cervical spine), or functional adaptive mechanisms aimed at reducing the pulse wave (with arterial hypertension) and ensuring the uniformity of blood flow.

Another cause of BCA lesions is nonspecific aorto-arteritis (NAA). It is observed in approximately 10-15% of patients and is a polyetiological autoimmune vasculitis with a predominant lesion of the aorta and main elastic arteries. NAA affects people aged 10 to 40 years, more often women (Mastykin: 2004, pp. 95-98; Suslina: 2001, pp. 26-28). NAA is characterized by multiple lesions of the branches of the aortic arch, often symmetrical, for example, two carotid and two subclavian arteries. Most often, the subclavian artery is occluded and almost twice as often - the left subclavian artery.

In 5-10% of cases, TIA is caused by relatively rare diseases that lead to damage (blockage or narrowing) of BCA and, as a result, to local ischemia of the GM. Acute and blunt vascular injuries with arterial thrombosis, BCA dissection, BCA fibromuscular dysplasia, and extravasal vascular compression.

Dissection of the precerebral and, less commonly, cerebral arteries accounts for about 2% of TIA cases and is more common in young women. Dissection of the ICA and PA may result from trauma, unsuccessful manipulation of the cervical spine, or developmental anomalies. A hematoma formed under the intima of an artery causes a narrowing of its lumen and can cause thrombosis or embolism.

The clinical picture of TIA is very diverse, but most importantly, with this pathology, there are no clear pathognomonic symptoms, the presence of which would help clinicians in the diagnosis and timely decision of tactics for the treatment of identified lesions, including the issue of surgical correction of the pathology. If we are talking about TIA in the carotid basin, then, as a rule, there is transient paresis or paralysis. In the TIA picture in the vertebrobasilar basin, the leading clinical symptom is dizziness.

The aim of our work was to study the methods of Doppler ultrasound and computed tomography in the diagnosis of TIA.

The study included 76 patients (47 men and 29 women) aged 45 to 80 years (mean age  $62.3 \pm 5.1$  years) The control group (15 patients) consisted of practically healthy individuals of the same age, without signs of vascular – cerebral insufficiency.

The etiological factors of TIA in our observations were: cerebral atherosclerosis 68.42% (52 patients) and a combination of cerebral atherosclerosis and hypertension 31.57% (24 patients). The course of hypertension in our observations was malignant with average Hg values of  $170 \pm 6.4$  mm Hg. and frequent increases in systolic blood pressure over 220 mm Hg, which aggravated the picture of cerebrovascular insufficiency.

In the clinical picture, outside the TIA attack, cerebral complaints of headaches, dizziness, aggravated by turning the head and changing the position of the body, sleep disturbances; decreased performance and memory impairment prevailed. In the presence of diffuse focal symptoms in the form of tendon anisoreflexia, symptoms of oral automatism, pathological foot signs, most of our patients, 80.2%, were diagnosed with discirculatory encephalopathy. It should be noted that in the majority of patients, clinical symptoms testified in favor of discirculatory encephalopathy, mainly in the vertebro-basilar basin. In the latter case, vertebro-basilar insufficiency of the II or III degree took place, which was also determined by the method of ultrasound Doppler ultrasound Doppler ultrasound (USDG BCS). The study of cerebral hemodynamics and the state of MAG was carried out by the method of Doppler ultrasound on the “VAZOSKAN” apparatus of the “SONICAID” company (England) with the use of sensors with a frequency of 2.4.8 MHz and diameters of 14, 10 and 6 mm. The studies were carried out in a city diagnostic center.

According to A.A. Spiridonov (1996), the pathology of only one carotid artery in 51.7% of cases leads to the development of TIA. The defeat of one vertebral artery in 38% of cases. The incidence of multiple BCA lesions in TIA ranges from 50 to 93.8%. In this regard, in order to determine the role of occlusive lesions in the development of TIA, Doppler ultrasound ultra sound Doppler ultrasound was performed. The study of cerebral hemodynamics and the state of MAG was carried out by the method of Doppler ultrasound on the “VAZOSKAN” apparatus of the “SONICAID” company (England) with the use of sensors with a frequency of 2.4.8 MHz and diameters of 14, 10 and 6 mm.

Magnetic resonance imaging studies were carried out in the conditions of the X-ray department of the 3 clinics of the Tashkent Medical Academy on the apparatus “Magnetom Open Viva” (Siemens) with a magnetic field strength of 0.2 Tesla in coronary and transversal projections using a common flexible radio-frequency coil for the body in a neutral position sick on the back.

Research results: The condition of patients upon admission in most cases, 80% (32 patients) were regarded by us as moderate. It is important to note that in most cases the severity of the condition was due to a large number of neurological symptoms, and not to impaired consciousness. When describing transient disorders, the following aspects were assessed: the duration and frequency of TIA, the presumptive vascular basin, the severity of the course, the prevalence of focal or cerebral symptoms. Moreover, in most of our observations, TIA passed with a predominance of focal symptoms over cerebral ones. Anamnestic features of patients who have undergone TIA are shown in Figure 1.

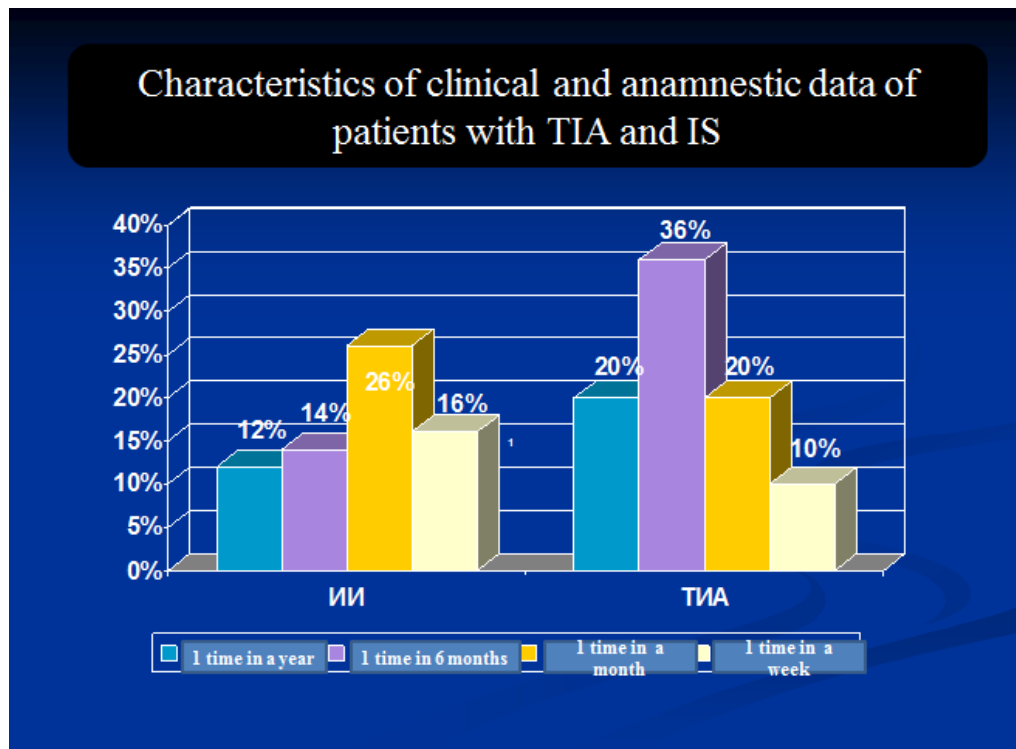


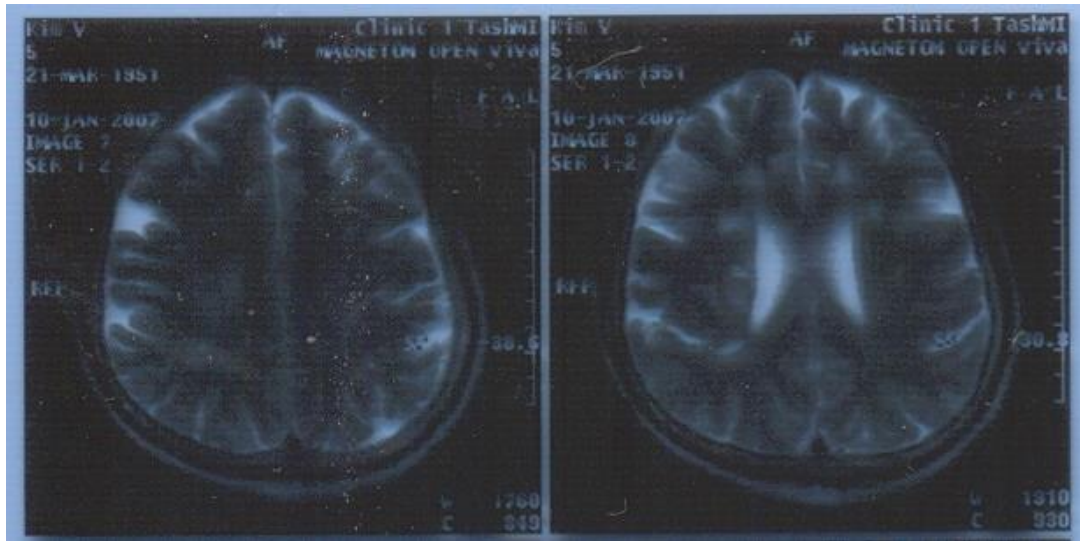
Fig. 1 Characteristics of clinical and anamnestic data of patients with TIA and IS

As can be seen from Figure 1, IS most often developed in patients with a frequency of TIA once a week or once a month. The highest risk of IS development was observed with the frequency of TIA once a week and reached 33.3%. The duration of TIA in this group of patients was up to 10-16 hours (according to the anamnesis).

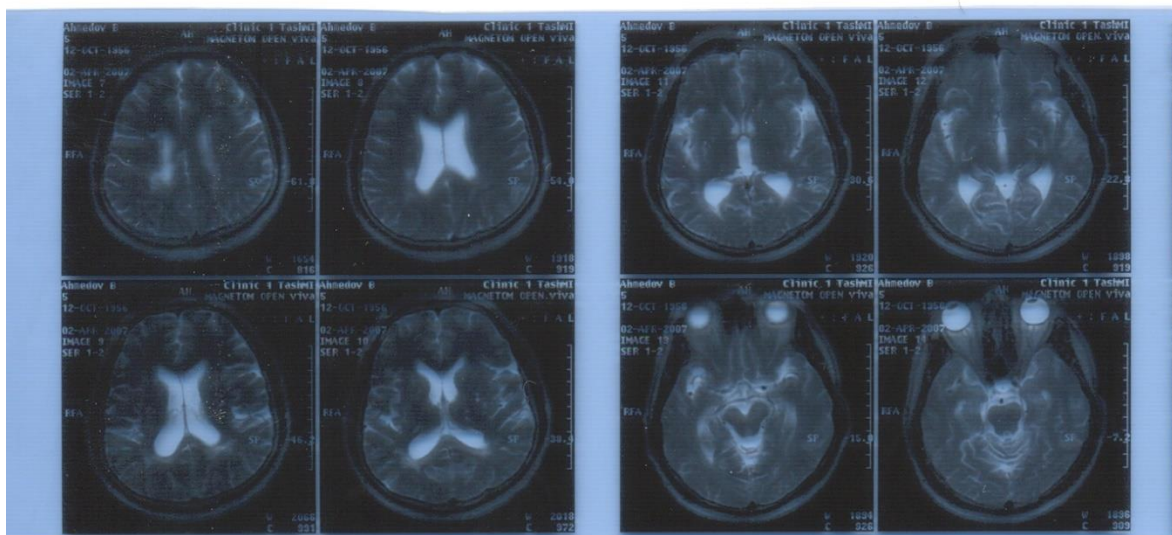
On the basis of clinical and anamnestic studies, we analyzed the relationship between the risk of stroke and the frequency of previous TIA in 18 patients who had suffered a stroke on the background of TIA (Fig. 2). In all cases, the vascular pool of the stroke coincided with the localization of the TIA. Moreover, as can be seen from the data presented, the incidence of stroke and TIA coincided when they were localized in the right carotid basin (31% and 37%, respectively). At the same time, TIAs in the left carotid basin were observed 3 times less often (18%) than strokes in the same basin (55%). On the contrary, TIAs in the vertebrobasilar were observed 3 times more often than strokes in the same vascular basin. The results obtained can be explained by the anatomical features of the structure of the vascular basin, as well as the compensatory capabilities of these vascular basins.

Magnetic resonance imaging (MRI) studies have revealed the dependence of the clinical picture of TIA on the severity of cerebral atrophy. In order to clarify the latter, on the basis of MR images, we calculated the indices of the index of the lateral and third ventricles. Our studies have shown that in the group of patients with frequent TIA (more than 2-3 times a month), the indices of the lateral ventricular index were 1.3 and were significantly higher than in patients with TIA 1 time in 6 months or in 1 year (0, eight). In addition, the dependence of MRI parameters on the degree of dyscirculatory encephalopathy and etiological factors leading to cerebrovascular insufficiency was revealed.

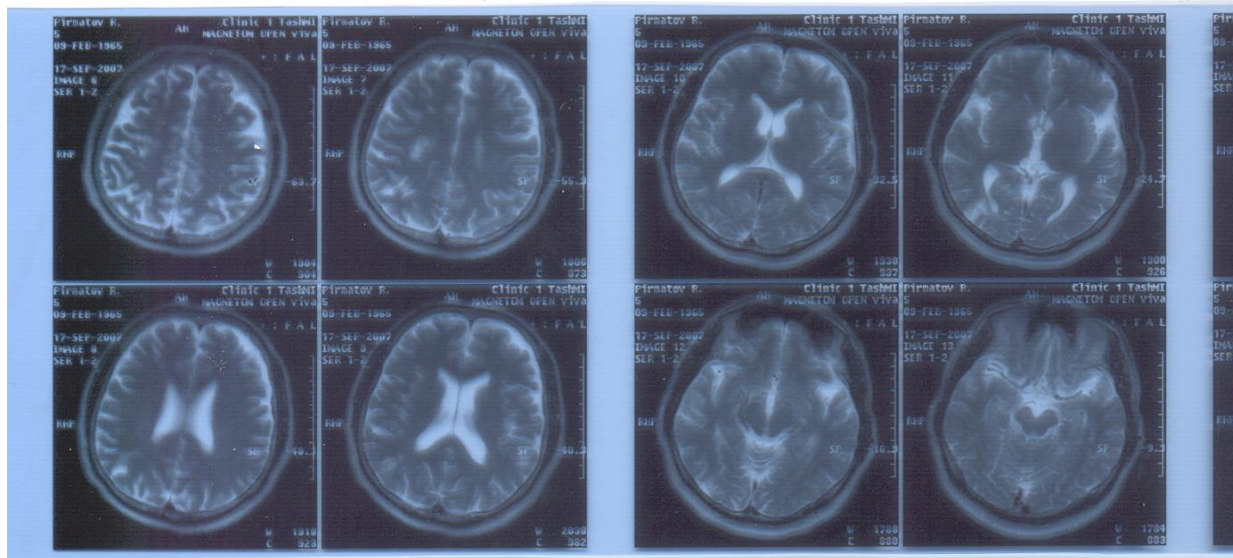
On MR images in the periventricular zone of the brain, multiple foci of low density, no more than 1 cm in size, were found.



The number of the above-mentioned foci also depended on the frequency of TIA. In addition, in the group of patients with a frequency of TIA more than 2-3 times a week, an expansion of the subarachnoid space and sylvian fissures was noted, which testifies in favor of external atrophy of the brain and indirectly indicates the state of cerebral hemodynamics. As a rule, the cause of TIA in the latter case was a combination of arterial hypertension and cerebral atherosclerosis.



In patients with TIA against the background of cerebral atherosclerosis, we revealed only the expansion of the sylvian fissures and the subarachnoid space, with the indices of the lateral ventricular index not significantly different from the indices of the control group.



## Conclusion

Thus, as our studies have shown, the clinical picture of TIA is distinguished by a variety of symptoms and the complexity of diagnosis, taking into account its retrospectiveness. The frequency, duration and vascular pool of TIA correlate with the risk of cerebral stroke. The clinical picture of TIA is also largely determined by the state of the brain, in particular the severity of its atrophy. The latter, depending on the etiological factor, manifests itself in the form of mainly external or internal forms. The number of foci of reduced density in the periventricular zone also directly depends on the frequency of TIA.

## References

- Gafurov B.G., Sh.Kh. Arifjanov et al. (2006) Journal of "Neurology" No. 1. – Tashkent.
- Gusev E.I., Skvortsova V.I., Platonova I.A. (2001) Therapy of ischemic stroke Consilium Medicum. Volume 3. N 5. - pp. 18-25.
- Mastykin A.S., Apanel E.N., Antonov I.P. (2004) Application of discriminant analysis to identify subtypes (models) of transient ischemic attacks. Medical News. No 7. – pp. 95-98.
- Mastykin A.S., Drivotinov B.V., Apanel E.N. (2004) Heterogeneity of the nosological concept of transient ischemic attack. Journal of Medicine. Belarus. No 4. – pp. 18-21.

- Suslina Z.A., Vereshchagin N.V., Piradov M.A. (2001) Subtypes of ischemic disorders of cerebral circulation: diagnosis and treatment of Consilium Medicum. Volume 3.- N 5. – pp. 26-28.
- Tarasova L.N., Kiseleva T.N., Fokin A.A. (2003) Ocular ischemic syndrome. – Moscow. – p. 174.
- Vereshchagin N.V., Suslina Z.A., Piradov M.A. et al. (2000) “Principles of diagnosis and treatment of patients with acute cerebrovascular accidents”. – Moscow.
- Vibors D.O., Feigin V.L., Brown R.D. (1999) Guide to cerebrovascular diseases. – Moscow.
- Vorlow Ch.P., Dennis MS, Gein J. et al. (1998) Stroke. A practical guide to the management of patients. – Saint Petersburg.
- Whisnant JP, Cartlidge NE, Elveback LR. (1978) Carotid and vertebral-basilar transient ischemic attacks: effect of anticoagulants, hypertension, and cardiac disorders on survival and stroke occurrence -- a population study. *Ann Neurol.* V.-3.- № 2. – pp. 107-115.
- Yavorskaya V.A. et al. “Medical Newspaper of Ukraine” No. 23/1 12.2006.
- Yevstigneev V.V., Fedulov A.S. (1998) State and prospects of studying vascular pathology of the brain. *Healthcare.* No 6. – pp. 26-32.

## Copyrights

Copyright for this article is retained by the author(s), with first publication rights granted to the journal.

This is an open-access article distributed under the terms and conditions of the Creative Commons Attribution license (<http://creativecommons.org/licenses/by/4.0/>).